

The Royal Tombs at Vergina Macedonia, Greece, Revisited A Forensic Review

Review Article

Delides GS*

Professor Emeritus of Pathology, School of Medicine, University of Crete, Greece.

Abstract

Three Royal Tombs were discovered at Vergina, Greece in 1977. In Tomb II, identified as the one of king Phillip, II father of Alexander the Great, and his wife Cleopatra, a ceremonial suit of armors including a pair of gilded greaves of unequal size, consistent with the documented lameness of Phillip II was found. A number of archaeologists and historians disagreed on the identification of the occupants in favor of Phillip III Arrhidaios and Eurydice the other royal couple likely to have been buried in the royal tombs at Vergina. Since Arrhidaios was unwarlike and intellectually weak they suggested that the ceremonial armor, was Alexander the Great's, disregarding the unequal size of the gilded greaves. An argument between scientists whether the bones found were cremated with flesh around them or degreased, was also published.

In a recent published paper examination of bones of a male found in Tomb I revealed a left knee ankylosis and a penetrating lance-related injury, regarded as proof that Tomb I was that of Phillip II. The authors support the view that the armor in Tomb II belonged to Alexander; no mention is made of the gilded greaves. There were no signs of inflammation or osteomyelitis found. One cannot easily explain how such a wound could not have damaged a main artery (fatal by that time) and accept that a year later the lesion healed and Phillip (if he was the wounded one) could have fought again at the battle of Chaeronea. The unequal size of the greaves has also taken into account and the armor being that of Alexander's should be rejected.

Keywords : Phillip's II Tomb; Vergina; Macedonia.

Introduction

In 1977 Manolis Andronikos, professor of Archaeology, Aristotelean University of Thessaloniki, Greece, discovered three Royal Tombs at Vergina, Macedonia, Greece. The place was that of ancient Aegai capital and burial site of the kings of the Macedonian dynasty. The excavation findings were reported in detail in his book: "Vergina, the Royal Tombs"[1] 1984.

The Tombs

Tomb I was looted but contained in its interior a superb wall painting depicting the "abduction of Persephone". It also contained the inhumed, but not cremated remains of a man, a woman and a neonate.

Tomb II was found with no signs of looting. It consisted of an antechamber and a chamber. The main chamber contained a sarcophagus in which there was a golden chest (larnax) bearing an embossed starburst, the emblem of the Macedonian Royal family (Figure 1). In the larnax there were the cremated remains of a middle-aged man and a golden wreath. In the antechamber there was a second golden chest with the cremated remains of a young woman in her 20s.

Parts of a ceremonial suit of armors, a cuirass with golden decorations, a golden and ivory ceremonial shield, an iron helmet, along with several other luxury items were found within the tomb. (Figures 2, 3). By the door connecting the antechamber to the chamber were found a golden "gorytos" (bow case) and a pair of gilded greaves of unequal size (the left shorter by 3.5 cm and narrower by 1.0 cm. than the right) (Figure 4). There were no

*Corresponding Author:

George S. Delides, M.D., PhD, Professor
Emeritus of Pathology, School of Medicine,
University of Crete, Greece,
108 Magnesia str. Dionysos 14576 Athens Greece.
Tel: +306944985504
E-mail: delides@otenet.gr

Received: March 03, 2016

Accepted: April 11, 2016

Published: April 15, 2016

Citation: Delides GS, (2016) The Royal Tombs at Vergina Macedonia, Greece, Revisited A Forensic Review. *Int J Forensic Sci Pathol.* 4(4), 234-239.
doi: <http://dx.doi.org/10.19070/2332-287X-1600056>

Copyright: Delides GS[®] 2016. This is an open-access article distributed under the terms of the Creative Commons Attribution License, which permits unrestricted use, distribution and reproduction in any medium, provided the original author and source are credited.

Figure 1 . The golden Larnax–Vergina Museum.



Figures 2, 3 . The shield and the cuirass - Vergina Museum.



length differences of the bones in the cremated male.

Luxury items indicating a Royal burial were found inside Tomb III. Within a silver urn, the cremated bones of less than 16 years old young man were found

The Occupants of Tomb II

Alexander the Great died in Babylon and buried in Egypt. The only two Macedonian kings likely to have been buried in the Royal tombs at Vergina, were Phillip II, Alexander's father and Phillip III, Arrhidaios, Alexander's paternal half-brother. Their wives Cleopatra and Eurydice respectively were buried with them.

Phillip II was a powerful king. His military and diplomatic skills secured Macedonian sovereignty all over Greece. He was elected by the Corinthian League to lead the army against the Persian Empire. He was assassinated in 336 B.C., at the age of 46 at Aegai, the Macedonian kingdom's capital, during his daughter's wedding celebration.

Phillip-III, Arrhidaios, succeeded Alexander the Great in 323 B.C. A king in name only, was weak and a puppet of his generals. Olympias (Alexander's mother) arrested Arrhidaios and his wife Eurydice in 317 B.C. and put Arrhidaios to death forcing Eurydice to commit suicide. Both were buried in Pydna but 17 months later, Cassander (husband of Alexander's half-sister Thessalonica)

exhumed, cremated and reburied the remains in a new tomb, along with Kynnana mother of Eurydice.


Andronicos identified Tomb II as that of Phillip II. He based his conclusion on a number of historical and archaeological findings presented in details in his book [1], refuting Arrhidaios and Eurydice as being the occupants of the tomb. He points to the argument that the luxury of the ceremonial armor does not consist with an unwarlike and weak king, as Arrhidaios is described. Since his presentation of the tombs findings in 1977, a number of archaeologists and historians disagreed with the identification of the occupants as Phillip II and Cleopatra, in favor of Arrhidaios and Eurydice. Among them E. Borza in a paper published in 1987 [2] suggested that the ceremonial armor (cuirass, helmet, bow-case, diadem, scepter and gold and ivory shield) were Alexander the Great's, brought from Egypt and buried in the tomb by Cassander.

M. Hatzopoulos in 2008 presented an analysis of previous discussions on Tomb-II, its occupants and the items found in them [3]. A long list of scholars, who shared Andronicos' position and challenged those attributing the tomb to Arrhidaios, is cited. According to R. Lane Fox "This article is the celestial starting point for anyone who takes up these subjects and their bibliography"[4]. Following Hatzopoulos' paper, E. Borza and O. Pelagia supporting their own views, published a re-examination of the question [5]. R. Lane Fox criticizes their main arguments

Figure 4 . Gorytos and greaves - photo from excavation Vergina Museum.



Figure 5 . Reconstruction of Phillip's head (University of Manchester).



and states, "I conclude with further observations on why the double Tomb II is certainly not Phillip III (Arrhidaios). That red herring can now be discarded from historical scholarship" [4].

Forensic controversy

Phillip II lost his right eye at the siege of Methone in 335 B.C. 18 years before his death when an arrow pierced his eye and disfigured his face.

The bones found in the "larnax" of Tomb II were examined and restored by Xyrotiris and Langensheidt [5] and then by University of Bristol anatomist J. Musgrave along with archaeologist J. Prag and medical illustrator R. Neave both of the University of Manchester. Xyrotiris and Langensheidt did not report findings of injuries found on the male skeleton. Prag et al presented their findings in the XII International Congress of Archaeology held in Athens in 1985 [6]. They describe a notch in the right eye-socket consistent with the Phillip's eye injury. A bony protuberance or "bone pimple" was reported as indication of healing and a distortion of the right side of the face as a skeletal response to the injury. They conclude: "If nature rather than fire was the culprit, then the suggestion that the bones belonged to a man known to have lost his right eye and perhaps sustained major injuries to much of the right side of his face 18 years before his death, becomes very attractive indeed" [6] R. Neave presented a reconstruction of Phillip's face showing a scar over his right eye. (Figure 5).

In 2000, professor Antonis Bartsiotas, Democritus University of Thrace, Greece, applied macrophotography to obtain a proper magnification to a normal size and study the microstructure of the wounds [7]. According to him "The "pimple" anatomically corresponds to the bony protuberance of the supraorbital notch and therefore does not constitute evidence of bone remodeling or callus formation". He also identifies the described "notch" as the normal "frontal notch" and states "bears no evidence of healing or callus formation as would be expected in a notch made by an arrowhead". Since Phillip III - Arrhidaios and Eurydice were buried "exhumed, cremated and reburied", whereas Phillip II and his wife were cremated, he supports the hypothesis that examination of the bones could be the hallmark of Tomb II identification [7].

Bones cremated with flesh around them are often referred to as 'green'. 'Dry' bones are completely degraded, either naturally or chemically as Arrhidaios bones were expected to be "Long bones cremated fleshed are fragmentary with marked warping; they assume a white, blue, and gray color and present frequent and parallel-sided transverse fractures that are either curved (thumbnail) or serrated" [7]. "Long bones cremated dry are nearly intact in size and form and show negligible warping; they assume a light brown color and present infrequent and straight transverse fractures ...or step fractures" [7].

Bartsiotas reports: "The preservation of the bones is excellent with minimal warping and transverse cracking that is straight.

The skeleton is almost complete, and light brown is the dominant color of the bones. Only the left proximal ulna presents some curved transverse fractures, probably the result of insufficient decomposition in this area. The right ulna is nearly perfect, with a longitudinal crack. This type of preservation of the male skeleton shows that most of the bones were dry when cremated; that is, they were buried for some time before they were cremated”.

Bartsiocas disregards Andronicos’ and other archaeologist and historian’s views favoring Phillip II as the occupant of Tomb II. Based on his identification of the “notch” as the “frontal notch” and the condition of the bones he concludes: “The skeletal evidence that shows a dry bone cremation leaves no room for doubt that Royal Tomb II belongs to Philip III Arrhidaeus”. He shares E.Borza’s view that the armor belongs to Alexander the Great.

In 2010, J. Musgrave and his colleagues published a paper criticizing Bartsiocas arguments [8]. Regarding the “pimple” and the “notch” they reply: “Our suggestion was tentative and we see no reason for departing from our cautious approach to the cause of these two features on a very small area on the upper facial skeleton which was also damaged. ‘Even if our suggestion that the upper margins of the eye sockets are asymmetrical is accepted, we still have to admit that trauma need not necessarily have been entirely responsible for the apparently exaggerated notch on the right.’” On the question whether the bones were cremated green or dry they comment: “One of us (HW) is a forensic pathologist, with wide experience of examining exhumed human cadavers and partially skeletonized remains discovered above ground. In his opinion, Arrhidaios’ body would still have

had putrefying skin and muscle attached to his limb bones, and rotting viscera filling his thoracic, abdominal and pelvic cavities after even seventeen months in the ground. It would not have become a dry and degreased skeleton. If the bones in the gold casket were burned dry, they could never have belonged to Philip III Arrhidaios because it would have taken them several years to achieve the state of dryness to produce the fracture lines classic of dry cremation” [8].

The Greaves

The pair of gilded greaves of unequal length found next to “gorytos” is undoubtedly part of the ceremonial armor. (Figure 6)

In 339 B.C. Phillip II was severely wounded at a battle against the Thracian tribe of Triballoi. A lance penetrated his left leg and killed also his horse. The King was supposed dead but he recovered and in August 338 he fought against the Athenians at the battle of Chaeronea. The wound left him lame.

After Andronicos and his presentation in his book, other researchers disregarded the greaves. They are not mentioned either by Borza or Bartsiocas who present the hypothesis that the Tomb II is the tomb of Arrhidaios and the armor belongs to Alexander (neither Alexander the Great nor Phillip III Arrhidaeus were lame). Since the leg-bones found in the golden larnax showed no differences in length it is difficult to speculate how the left tibia can fit in a shorter greave. (Figure 7)

In my paper of 1986 [9] I proposed the hypothesis that the reason was a posterior dislocation of the knee, a result of a wound on

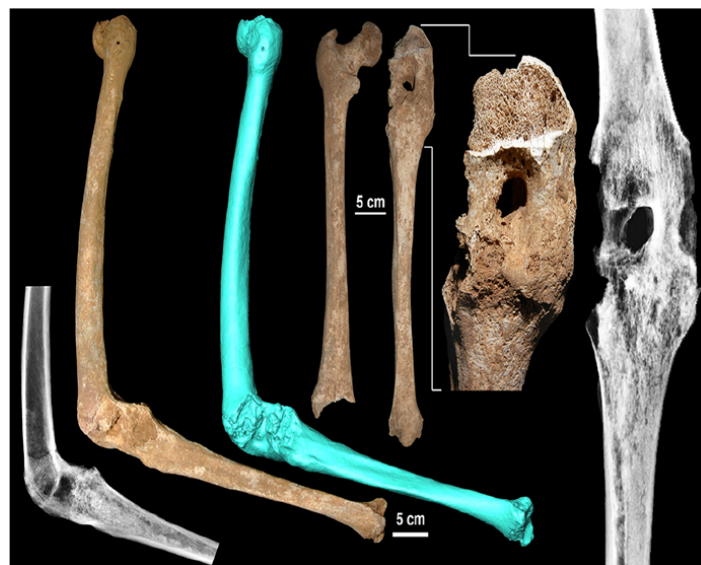Figure 6 . The greaves- Vergina Museum.



Figure 7 . The male skeleton of Tomb II -Vergina Museum.




Figure 8 . Knee ankylosis and hole. Tomb I (Courtesy of A.Bartsiokas).



the thigh as presented in old medical literature accounting for leg shortness and consequent lameness.

A Recent Research

A research study on the bones found in Tomb I was published in August 2015 by A. Bartsiokas and his colleagues [10]. The inhumed remains of a man, a woman and a neonate were examined. CT scanning, radiography, macrophotography and surface scanning were applied to the bones.

Results revealed a hole likely produced by a penetrating weapon (a lance) below the level of the femoral condyles. “A remarkable flexional ankylosis of the left knee, which resulted in the fusion of the tibia with the femur” was also revealed. There were no characteristic clues of infection or/and osteomyelitis found on the femur or the tibia (Figure 8).

According to the above authors “This finding indicates that the active inflammatory process stopped years before death. If there was an infection, this was resolved long before the time of his death. Bony synostoses with no obvious signs of infection are commonly produced by severe injuries and therefore we deduce that the ankylosis was caused by a severe wound to the knee”. Ankylosis is consistent with the historically documented lameness of Phillip and the authors conclude: “Phillip II, his wife Cleopatra and their newborn child are the occupants of Tomb I, overturning the current opinion of the archaeological establishment that Tomb II belongs to Phillip II. As a consequence, Tomb II could only belong to King Arrhidaeus and Eurydice and may well contain some of the armor of Alexander the Great”.

The authors disregard the pair of greaves (the left consisting with Phillip’s lameness) and how can it be part of Alexander’s armor. They also disregard that no other female skeleton was found in Tomb II although Kyrannana is supposed to be buried in the Tomb of Arrhidaeus and Eurydice.

Discussion

Analysis of the examined bones by Bartsiokas et al revealed a severe penetrating wound to the left knee. The site of the hole as presented in pictures (Figure 8) indicates the possible rupture of the popliteal artery or one of its main branches and perhaps of the sciatic nerve or one of its branches. Such an artery rupture by that time would have been fatal, despite Bartiokas et al comment that “The recovery of Phillip II after this terrible knee joint wound is a remarkable event in an era without antibiotics. It demonstrates remarkable skill by his doctors to avoid bleeding”. Nerve trauma would probably cause leg paralysis. Un-necessary to give credit to a medical miracle of unknown circumstances!

Ankylosis due to osteoarthritis following knee injury can be the result of a severe wound and since sequelae of inflammation and osteomyelitis were not found on the bones, it appears that they were resolved before this man’s death. Phillip’s death occurred three years after the battle against Triballoi in 339 BC. The king fought at the battle of Chaeronea against the Athenians leading the right flank of his army in 338 B.C., a year after his wound. Were inflammation and/or osteomyelitis resolved in less than a year without a further infection?

Regarding the wound’s site, Justin and Plutarch mention the thigh and Demosthenes and Athenaeus, the leg [11]. Nobody is mentioning the knee, although the knee is a distinct anatomical site in Ancient Greece as cited by Hippocrates [12].

It is also mentioned that the lance that wounded Phillip’s leg, has also killed his horse [10]. Penetration of bone would have caused resistance reducing the force of the strike and its power to kill a horse as well. The scenario could be a little different i.e. the lance hit the horse first severing the horse’s jugular and by then weakened hit Phillip’s knee, in that trajectory. It appears that such a strike from a lance head would probably result in bone fracture and not just “a hole”. A penetrating wound at the thigh without bone damage, as recorded by ancient historians [11], may even cause compartment syndrome complicated by neurological deficits and motor weakness

of the lower extremity [13, 14].

Conclusion

The evidence produced by Bartsiokas et al [10] is not conclusive and has therefore been inadequate to overturn and disregard “the current thesis that Tomb II belongs to Phillip II” based on the archaeological findings [10]. The unequal size of the greaves indicating a lameness of the left leg cannot easily be disregarded and since the greaves belong to a ceremonial armor, the armor is not that of Alexander’s. As far as the exhumed bones of the man in Tomb I who was not honored with a “Royal” burial as in Tombs II and III, one can think of the possibility that he died from a penetrating wound causing fatal bleeding or infection. Knee injury i.e. meniscus tear leading to stiffness and ankylosis from osteoarthritis occurred long before his fatal wound.

Acknowledgment

Thanks to Drs Antony Okos and John Panayiotides for their comments.

References

- [1]. Andronicos M (1984) Vergina. The Royal Tombs. Ekdotike Athinon, Athens.
- [2]. Borza EN (1987) The Royal Macedonian Tombs and the Paraphernalia of Alexander the Great. *Phoenix* 41(2): 105-121.
- [3]. Hatzopoulos MB (2008) The Burial of the Dead (at Vergina) or the Unending Controversy on the identity of the Occupants of Tomb II. *Tekmeria* 9: 91-118.
- [4]. Fox RL (2011) Dating the Royal Tombs at Vergina. *Brill's Companion to Ancient Macedon Studies in the Archaeology and History of Macedon 650BC-300 AD.* 21-27.
- [5]. Xirotiris NI, Langenscheidt F (1981) The Cremation from the Royal Macedonian Tombs of Vergina. *Ephemeris* 142-160.
- [6]. Prag AJNW, Musgrave JH, Neave RAH (1985) The appearance of the Occupant of the Royal Tomb at Vergina. *Proceedings of XII International Congress on Classical Archaeology* 226-231.
- [7]. Bartsiokas A (2000) The eye injury of King Philip II and the skeletal evidence from the royal tomb II at Vergina. *Science* 288(5465): 511-514.
- [8]. Musgrave J, Prag AJNW, Neave R, Fox R L, White H (2010) The Occupants of Tomb II at Vergina. Why Arrhidaios and Eurydice must be excluded. *Int J Med Sci* 7(6): s1-s15.
- [9]. Delides GS (1986) The differences of the Greaves found in the Royal Tomb at Vergina and the Lameness of Phillip II. *Archaiology and Arts* 18: 63-64.
- [10]. Bartsiokas A, Arsuagab JL, Santos E, Algaba M, Gómez-Olivenciad A (2015) The lameness of King Philip II and Royal Tomb I at Vergina, Macedonia. *PNAS* 112(32): 9844-9848.
- [11]. Riginos AS (1994) The wounding of Philip II of Macedon: Fact and fabrication. *J Hell Stud* 114: 103-119.
- [12]. Hippocrates: *PeriAgmon Papyros Athens* (1937) 53-54.
- [13]. Ojike NI, Roberts CS, Giannoudis PV (2010) Compartment syndrome of the thigh: a systematic review. *Injury* 41(2): 133-136.
- [14]. Schwartz JT Jr, Brumback RJ, Lakatos R, Poka A, Bathon GH, et al. (1989) Acute compartment syndrome of the thigh. A spectrum of injury. *J Bone Joint Surg Am* 71(3): 392-400.